



© Bozhib | Dreamstime.com

Dental impression problems: Identifying and managing

Gregori M. Kurtzman, DDS, MAGD, DADIA, DICOI, DIDIA, FACD, FADI, FPFA

PUBLICATION DATE: SEPTEMBER 2021

EXPIRATION DATE: AUGUST 2024

EARN

3 CE
CREDITS

Dental impression problems: Identifying and managing

Educational objectives

1. Identify common impression problems.
2. Correct common impression problems.
3. Improve impression quality and avoid impression problems.
4. Select impression materials that are best suited for specific restorative objectives.

Abstract

Restorative dentistry, be it for fixed or removable prosthetics, requires an impression of the teeth and area to be restored for the laboratory to fabricate the desired restorations. Traditional physical impressions are still utilized the majority of the time to capture the needed information for the lab. Impression material viscosity selection will vary depending on what type of prosthesis is to be fabricated, which tray is being used, and whether the preparations are on natural teeth, implants, or an edentulous arch. Problems may arise during impression-taking that can compromise the lab's ability to fabricate the restoration or may affect the accuracy and fit of the finished prosthesis. Identifying impression problems is part of the process, but how to manage these to improve the quality and accuracy of our impressions is critical to fixed and removable prosthetics.

This continuing education (CE) activity was developed by Endeavor Business Media with no commercial support.

This course was written for dentists, dental hygienists, and dental assistants, from novice to skilled.

Educational methods: This course is a self-instructional journal and web activity.

Provider disclosure: Endeavor Business Media neither has a leadership position nor a commercial interest in any products or services discussed or shared in this educational activity. No manufacturer or third party had any input in the development of the course content.

Requirements for successful completion: To obtain three (3) CE credits for this educational activity, you must pay the required fee, review the material, complete the course evaluation, and obtain an exam score of 70% or higher.

CE planner disclosure: Laura Winfield, Endeavor Business Media dental group CE coordinator, neither has a leadership nor commercial interest with the products or services discussed in this educational activity. Ms. Winfield can be reached at lwinfeld@endeavorb2b.com.

Educational disclaimer: Completing a single continuing education course does not provide enough information to result in the participant being an expert in the field related to the course topic. It is a combination of many educational courses and clinical experience that allows the participant to develop skills and expertise.

Image authenticity statement: The images in this educational activity have not been altered.

Scientific integrity statement: Information shared in this CE course is developed from clinical research and represents the most current information available from evidence-based dentistry.

Known benefits and limitations of the data: The information presented in this educational activity is derived from the data and information contained in the reference section.

Registration: Rates for print CE have increased due to the manual nature of producing and grading courses in this format. For a lower-cost option, scan the QR code or go to dentalacademyofce.com to take this course online. **MAIL/FAX:** \$69 for three (3) CE credits. **DIGITAL:** \$59 for three (3) CE credits.

Cancellation and refund policy: Any participant who is not 100% satisfied with this course can request a full refund by contacting Endeavor Business Media in writing.

Provider information:

Dental Board of California: Provider RP5933. Course registration number CA code: 03-5933-21089. Expires 7/31/2022. "This course meets the Dental Board of California's requirements for three (3) units of continuing education."



Endeavor Business Media is a nationally approved PACE program provider for FAGD/MAGD credit. Approval does not imply acceptance by any regulatory authority or AGD endorsement. 11/1/2019 to 10/31/2022. Provider ID# 320452. AGD code: 690



Endeavor Business Media is designated as an approved Provider by the American Academy of Dental Hygiene, Inc. #AADHPNW (January 1, 2021-December 31, 2022). Approval does not imply acceptance by a state or provincial Board of Dentistry. Licensee should maintain this document in the event of an audit.

ADA CERP[®] Continuing Education Recognition Program

Endeavor Business Media is an ADA CERP-recognized provider.

ADA CERP is a service of the American Dental Association to assist dental professionals in identifying quality providers of dental continuing education. ADA CERP does not approve or endorse individual courses or instructors, nor does it imply acceptance of credit hours by boards of dentistry.

Concerns or complaints about a CE provider may be directed to the provider or to ADA CERP at ada.org/cerp.



Dental Academy of Continuing Education™

Go online to take this course.
DentalAcademyofCE.com

QUICK ACCESS code 21089



Introduction

Impression-taking is a critical and technique-sensitive step in the fabrication of fixed and removable prosthetics. This can also be a frustrating stage during treatment, both to the clinician and laboratory technician. Potential complications need to be identified and corrected prior to sending the impression to the lab for fabrication of the prosthesis. This course will address some common difficulties, factors that might cause impression errors, and methods to correct and avoid complications related to impression capture for fixed and removable prosthetics.

Inadequate marginal detail

Lack of adequate marginal detail regarding fixed prosthetic impressions is the primary complaint laboratory technicians voice with the impressions they receive daily. The most critical aspect of an impression for fixed prosthetics is marginal detail, as it indicates where the restoration will terminate on the prepared tooth. Failure to capture the true details of the preparation margin will result in inadequate fit of the crown, onlay/inlay, or bridge, resulting from open or overhanging restoration margins. Marginal voids in the impression are the result of either insufficient retraction or fluid accumulation that prevented the impression material from flowing around the preparation (figure 1). This results in the laboratory attempting to guess where the preparation terminated on the tooth, and often results in a poor-fitting crown. Improved retraction methods can help avoid these issues, using syringeable hemostatic agents that come in paste form (e.g., Retrac: Centrix; Exspasyl: Kerr Sybron; Traxodont: Premier Dental Products).¹⁻³ These retraction

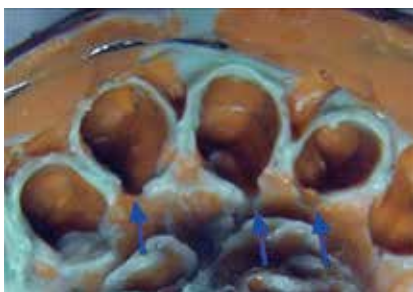

FIGURE 1: Impression demonstrates the appearance of marginal voids (arrows).

pastes are placed into the gingival sulcus following preparation and held under pressure with a GingiCap (Centrix Dental) or Comprecaps (Coltène/Whaledent), creating dilation of the sulcus and resulting in hemostasis. They are easier to use than retraction cords and are flushed from the sulcus with the air/water syringe prior to placement of a light-body impression material into the sulcus and over the preparation. A hemostatic-containing impression material (NoCord: Centrix Dental) was introduced to replace the separate step to achieve retraction/hemostasis, reducing treatment time without affecting the accuracy of the impression, and this becomes part of the final impression.

When adequate retraction is achieved, the impression material is able to flow around the preparation's margins, capturing the details, so that the lab is able to visualize where the practitioner wants the restoration to terminate on the tooth (figure 2). This improves the accuracy of the restoration's fit and decreases chair time to insert the restoration.



FIGURE 2: Appearance of an impression with accurate marginal detail.

Alternatively, lasers have been increasingly used for these procedures, replacing the need for retraction cords and pastes. These lasers include diode (Picasso: AMD Lasers; Epic: Biolase; Precise LTM: CAO Group); Er:YAG (LiteTouch: Light Instruments Ltd; Waterlase: Biolase); and Nd:YAG (Lightwalker: Fotona; Periolase MVP-7: Millennium Dental Technology). These are used to trough the sulcus, widening it to better visualize the prepared margin. Hemostasis is also achieved. In the past, electrosurgery was also used for sulcus dilation and hemostasis. However, lasers are kinder to the tissue without the potential for recession that has been

reported with electrosurgery.⁴

Vinyl polysiloxane (VPS) is the most widely used impression material available, with the largest market share compared to polyether-type impression materials. VPS impression materials were introduced more than 30 years ago. Those early VPS materials were hydrophobic (repelled by water), creating potential issues if any fluids were on the preparation's margins. The chemistry was improved by the VPS manufacturers to make the material more hydrophilic (adaptable to wet surfaces). But any moisture, such as water, saliva, or blood, trapped at the internal angles of the preparation can lead to bubbles in the impression.

Internal bubbles

Larger, less sharply defined internal bubbles result from fluid accumulation. Smaller, well-defined internal bubbles result from air entrapment (figure 3). Bubbles on the margins of the preparations can negatively affect the fit of the prosthetic as the lab has to estimate where the margin is at that spot on the preparation. When those bubbles occur on the internal line angles of an inlay or onlay preparation related to fluid accumulation, preventing the impression material from contacting the entire surface, the result is a substandard fit of the restoration. When they occur due to air entrapment, the fit of the restoration will not be compromised, and that void will be filled by the cement used to lute the restoration to the tooth.

Bubbles occurring due to fluid accumulation may be large enough to affect the long-term success of the luting agent, which must now fill a wider space when nonresin luting materials are utilized. The thicker the luting material, the weaker the interface between the restoration and underlying tooth. This may also lead to the prosthetic material being thinner than recommended over the area where the void was in the model, weakening the restoration, with material failure of the restoration resulting under function. This becomes more critical when using all-ceramic materials, as they require minimum thicknesses to perform as expected.

Use of a wash impression to reline a completed impression when a void is

noted is difficult in a two-step impression technique as complete seating of the impression may be hampered. When a two-step approach is considered, removal of impression material interproximally in the set impression with scissors will allow full reinsertion of the impression intraorally. Additionally, new wash material should be placed in all the tooth areas on the side of the impression before reseating the previously set impression. Placement of wash material only on the prepared teeth may result in a “stepped” impression and lead to a restoration that is not accurate related to the occlusion. When a dual-arch tray is used, if the bulk of the set impression material in the tray is a medium viscosity, relining it may allow the tray and previous impression material to spring laterally due to the hydraulic pressure of seating the impression with new VPS injected into it. The result is spring-back when removed intraorally, creating distortion in the resulting model and an inaccurate restoration that will not fit the prepared tooth. This can be avoided by creating lateral holes through the set impression material and tray to allow the new VPS to vent when seated back intraorally. Use of stiffer VPS in the tray can avoid tray distortion and will be discussed further in this course.

Large, internal, ill-defined areas in these preparations is usually due to fluid accumulation. Air entrapment may also be a factor in narrow, deep inlay preparations. These types of errors may be avoided by thorough flushing and drying of the preparation prior to impression-taking. Placing an intraoral impression tip into the deepest part of the preparation floor and extruding a light-body VPS material to backfill the preparation, making sure to keep the tip in the material as it is expressed, will force air out of the preparation, decreasing entrapment potential.

When an air bubble remains on the cast after the impression is poured, a corresponding void will be created in the prosthetic material. This should not interfere with seating of the restoration or affect the restoration’s properties when the bubble/void is small, and the air bubble will be filled with the luting agent. When removed from the cast prior to restoration

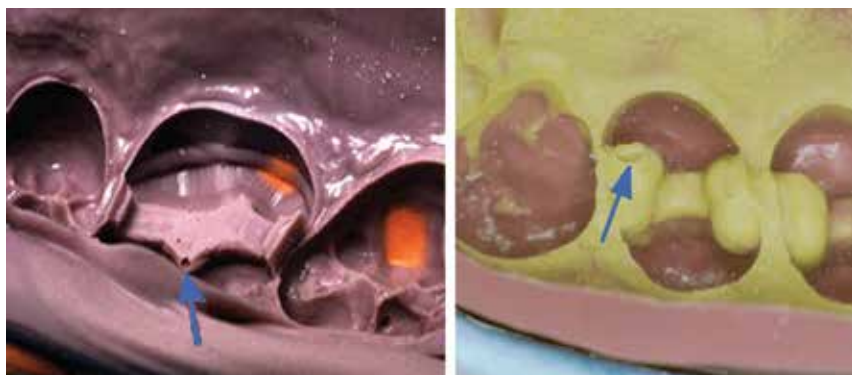

FIGURE 3: A bubble is located on the internal detail of the impression of the preparation (blue arrow).

fabrication, these spots can often prevent complete seating as alteration of the cast’s surface may not match what is present intraorally on the preparation, requiring the practitioner to modify the internal surface of the restoration chairside to allow it to seat on the preparation fully. Identification of any premature internal contacts can be performed with a paint-on occlusion indicator (e.g., Accufilm IV: Parkell Inc; Arti-Spot: Bausch). The laboratory can block out around these tiny internal bubbles prior to fabrication to decrease chair time.

Marginal tears

Marginal impression tears usually occur when a syringeable wash material with insufficient tear strength is used (figure 4). Tear strength varies from manufacturer to manufacturer and between viscosities. Lower viscosity impression materials are more likely to tear in the sulcus due to their thinness expressed subgingivally. The deeper the sulcus, the thinner the wash material expressed into it, and the higher the potential for it to tear

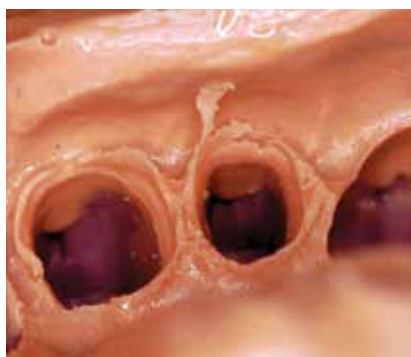

FIGURE 4: Wash material following development of a tear at the margin aspect of the impression.

when removed intraorally. Removal of the impression prior to complete setting of the wash material may also cause marginal tearing, so it is important to follow the manufacturer’s recommendation on setting time.

Should an impression need to be retaken due to sulcular material tearing, any remnants of the original impression material must be removed from the sulcus and thin, torn wash material trimmed from the set impression with a scissor prior to relining the impression. Additional tissue retraction may be indicated to widen the sulcus to facilitate thicker sulcular impression material and prevent tearing of the material again when removed intraorally. Syringeable hemostatic liquid materials (ViscoStat Clear: Ultradent; Quick-Stat Free: Vista-Apex Dental Products) can be used to limit the amount of fluid evident in the treatment area, and the patient can be instructed to occlude into a cotton cap for several minutes, thereby physically pushing the tissue away from the tooth and forcing the hemostatic material deeper into the tissues.^{5,6} Switching to a more viscous wash material may further prevent development of another tear.

Drags and pulls

A common complication encountered when using high-viscosity impression materials (i.e., putty or heavy-body materials) are drags and pulls. A drag results when long, rounded depressions that resemble the cuspal edges of the teeth are left in the impression material upon insertion of the tray, as the material does not readily flow completely around the preparation or teeth (figure 5). A pull,

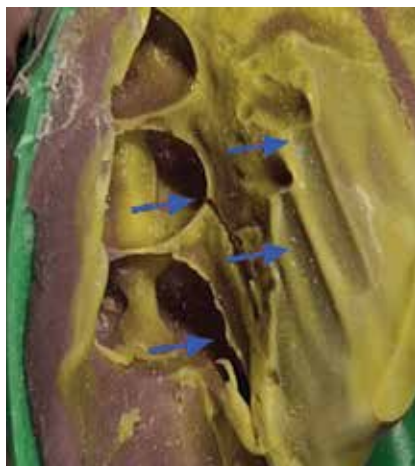


FIGURE 5: Drags appear as rounded depressions in the impression material.

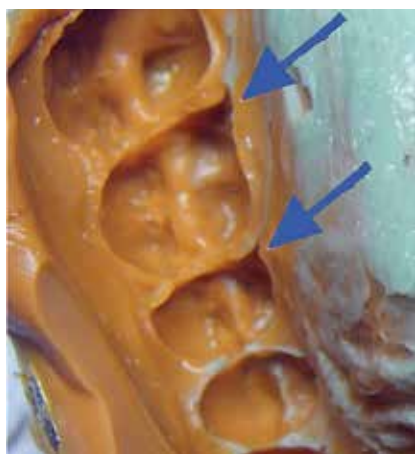

FIGURE 6: Folds in the impression (blue arrows).

also referred to as a fold, results when a fold is created in the impression material, typically at the gingival aspect (figure 6). These types of deformities can result from:

- Teeth rebounding off the tray and sliding into position
- Impression material inserted beyond its working time (no longer in its most fluid state)
- Failure of the impression material to adapt to the teeth
- Insertion of the tray in one motion

Drags and pulls can be avoided by using a less viscous material that is either syringed around the teeth or placed over the more viscous material in the tray prior to insertion. Using a combination of syringing the wash material over the teeth and placing some over the tray material prior to inserting it intraorally has a greater potential of avoiding drags and

pulls. Correction of a pull in the impression can be accomplished by removal of the interproximal impression material, so the impression can be reinserted without interference, and then filling all the teeth areas of the set impression prior to reinserting the tray intraorally with a syringeable impression material (light or extra-light). Drags, on the other hand, often are not correctable by adding additional material, as they may have caused distortion of the tray, and taking a new impression is advised versus attempting to reline the impression. Avoiding contact between the tray and the teeth when inserting the tray will help avoid drag deformations.

Impressions for removable prosthetics

Impressions for fabrication of partial dentures are similar to those for fixed prosthetics in the selection of VPS viscosity and type of tray used. These impressions are taken with a full-arch tray. With the quality of impression materials available, impressions can be taken with a stock tray, and custom trays are not required. The selected tray is filled with a medium viscosity (monophase) VPS, and a light-body VPS is placed over the teeth in the arch to prevent voids in the gingival aspect of the resulting impression, and the tray is seated.

An impression for a full denture requires a different approach and selection of impression viscosity. Typically, the margins of the tray are border-molded to customize the tray for the patient's arch. This can be performed with a heavy-body VPS placed on only the tray's flanges and inserted to capture the vestibule. Upon setting, the tray is removed, and the border molding captured with the heavy-body material can be trimmed with a scalpel. The tray is then filled with a medium-body VPS, also covering the border-molded flanges, and reinserted intraorally to capture the arch's details for the lab. Use of the medium-body impression material will not distort or deform the tissue, capturing it in its rested, or natural, state, which can happen when a more viscous material is used. These full-denture impressions typically do not require use of a wash

material, and the medium-body material will adequately capture all needed details of the arch. But, if the ridge is "flabby" at the crest, as evidenced by easy moveability when pressed laterally, light-body VPS should be placed in the tray at those areas to prevent tissue distortion and capture the ridge in its resting position.

Tray selection

Tray selection is important to capture the needed area without distortion and provide the details of the teeth being restored or the entirety of the arch when removable prosthetics are planned.^{7,8} The tray—either a dual-arch tray (also known as a triple tray) when fixed prosthetics limited to part of the arch is planned, or a stock full-arch tray for removable prosthetics or the full arch is required for fabrication of fixed prosthetics—should be large enough to encompass all needed areas without contacting the soft tissue or teeth that may cause distortion of the resulting impression (figure 7). The completed impression should not demonstrate any show-through of the tray in the set impression material. Full-arch trays are available in small, medium, and large. Arch shape varies by manufacturer, with some trays round and others squarer. It is recommended to have full-arch trays in the three sizes for both the maxillary and mandibular arches from two different manufacturers so that a wider selection of stock trays is available. The stock full-arch tray needs to be long enough to capture the entire arch from the hamular notches or retromolar pads to the most anterior aspect of the buccal vestibule. A tray that is too narrow may prevent adequate seating, leading to missing required arch detail (figure 8). Metal trays may be bent to widen them in the posterior, but modifications to the anterior of the tray can be difficult. Plastic stock trays are easier to customize for a particular patient. An alcohol torch may be used to heat the plastic tray and readapt the flanges to fit a specific patient, or the tray can be modified with an acrylic bur.

VPS impression materials have the most accuracy when they are not too thick. All materials have polymerization shrinkage upon setting, and this is a percentage

of the material's mass. This can be problematic when using a stock tray designed for capture of an arch with teeth when taking an impression for a full-arch denture, as the impression material is very thick due to lack of close proximity between the tray and arch. Full-denture impression trays have been designed to place the tray closer to the arch and reduce the thickness of the impression material, improving accuracy of the impression. These are fabricated from plastic that can be heated and modified for particular patient cases and in multiple sizes for each arch. With these criteria in mind, Dr. Joseph Massad developed Massad denture trays, which are available from various manufacturers such as Zest Dental Solutions, Nobilium, and Dentsply Caulk (figure 9).

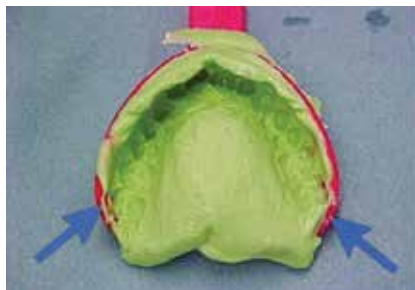

FIGURE 7: Use of an impression tray that's too small leads to contact with the tray borders and the teeth (arrows).

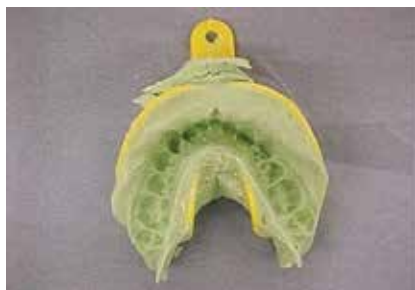

FIGURE 8: The impression tray has not been inserted far enough posteriorly to capture the details of the most distal teeth. Note: Excess material was evident in the anterior region due to poor tray placement.



FIGURE 9: Massad full-arch denture trays for the maxillary and mandibular arches.

Dual-arch trays

Frequently, partial-arch fixed prosthetic impressions are captured with a dual-arch tray, allowing teeth being restored and their opposing dentition plus the interarch bite to be taken with a single impression. Dual-arch trays are available in different widths that can accommodate different arch sections. It is best to have a variety of these trays to accommodate each patient's arch size and shape. These trays are available for anterior, posterior, quadrant, three-quarter arch, and full-arch impressions. Following capture of the impression, any show-through of the tray in the impression indicates that the tray used was either positioned improperly or was too small or narrow for that patient's arches (figure 10). Contact of the tray by soft tissue may cause distortion of the resulting impression and a restoration that does not fit the prepared tooth.

When using dual-arch trays, it is important to capture at least one full tooth (or the equivalent space) both mesially and distally to the tooth to be restored. Failure to provide this in the impression may make it difficult for the laboratory to properly mount the casts and achieve an accurate occlusion (figure 11). Additionally, the lab may have difficulty fabricating the contact to the partially captured adjacent tooth, compromising the final result of the restoration. Dual-arch trays work well for fixed prosthetic applications as long as the patient has holding occlusal contacts in the section of the arch to be restored, ideally mesial and distal to the intended teeth being restored.

When the tray is inserted and the patient occludes, it is important that maximum intercuspation be observed on the adjacent side (figure 12). When using anterior dual-arch trays, it is often difficult to determine if the patient has occluded fully, so a separate bite should be provided to the laboratory in a very rigid VPS material designed for occlusal records. It is recommended that the lab be instructed to use the separate bite record provided to mount the case and avoid hand articulating the casts or using the dual-arch impression to determine occlusion. Wax bites should not be used, as they are unstable in transport to the lab due to changes in temperature during shipping. Posterior

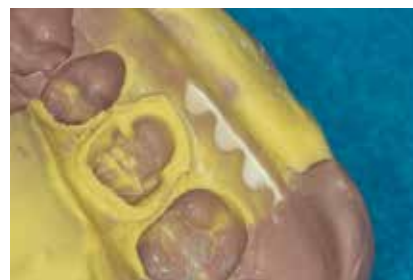

FIGURE 10: Contact of the tray with the soft tissue may cause potential tray distortion.

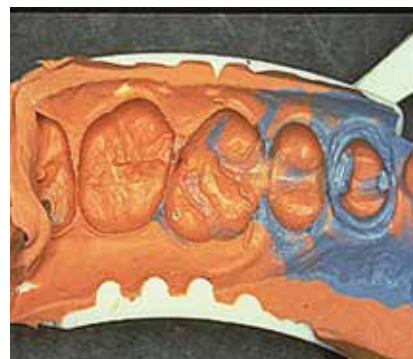


FIGURE 11: Appearance of an impression following inadequate capture of the teeth surrounding the tooth to be restored.

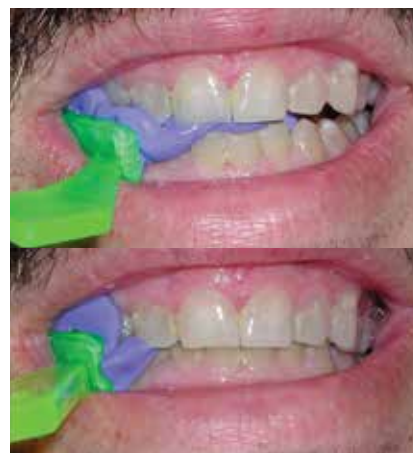

FIGURE 12: (Top) Inadequate occlusal intercuspation during impression with a dual-arch tray. Note the open bite on the left side. (Bottom) Proper intercuspation during impression. Note full intercuspation on the left side.

and three-quarter quadrant trays have a plastic distal loop on the tray to stabilize the tray during insertion. It is critical that the patient not occlude on this loop or contact between the tuberosity and retromolar pad, as this will lead to distortion of the tray and resulting spring-back when the tray is removed (figure 13).

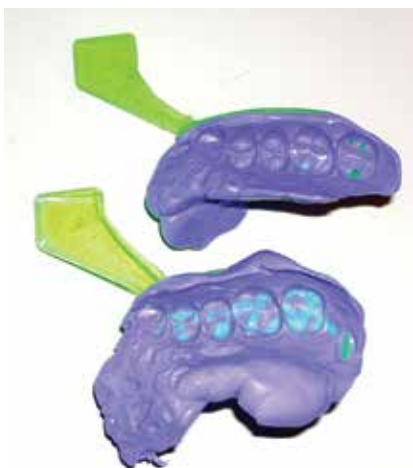


FIGURE 13: (Top) Contact of the posterior teeth was evident with the distal aspect of the plastic tray. (Bottom) A lack of contact with the tray is demonstrated and maximum intercuspation was developed at the contact area.

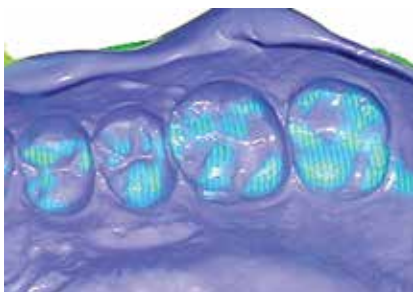


FIGURE 14: Proper occlusion into the impression as evidenced by show-through of the mesh of the dual-arch tray at the occlusal contacts.

Upon dual-arch tray impression removal, the clinician should be able to see contacts through the material to the tray's mesh on teeth that are not prepared where the teeth occluded, ensuring that the bite was properly captured (figure 14). Holding the tray up to the light should reveal illumination at these contact points. An impression that was improperly occluded will show lack of occlusal shine-through and thicker material between the arches. If there is any chance that the laboratory cannot verify the occlusion, a separate bite should be taken with an appropriate VPS bite registration material and included with the case.

Tray separation

Impression material separation from the tray may not be obvious until the restoration is returned and tried intraorally

(figure 15). The resulting deformation may be overlooked when using trays with slots and holes to lock the impression material, and they can occur with VPS, polyethers, and even alginate. The greater the viscosity of the impression material, the higher the potential for the material not to lock into the retention areas of the tray. Tray adhesive is recommended with all impressions to create a chemical bond between the tray and impression material, to help eliminate impression separation from the tray.⁹ Additional holes for mechanical retention may also be placed with a lab bur in stock trays if needed. Specific tray adhesives are available depending on the type of impression material being used (VPS, polyether, or alginate). Each impression material's chemistry is different, so it is advised that the clinician use the tray adhesive from the same manufacturer as their impression material to ensure chemical compatibility between the adhesive and impression material. Following application of the adhesive to the tray, allow the adhesive to dry for at least two minutes prior to applying the impression material. The adhesive can be applied at the beginning of the appointment and will then be dry and ready when it is time to take the impression.

Tray distortion

Trays may distort when they come in contact with the teeth or tissue. Dual-arch trays are not rigid due to their design, which allows intercuspation into the tray capturing both arches. Distortion of dual-arch trays is due to their more flexible nature as the patient occludes, especially if soft tissue contacts the rigid part of the tray or posterior loop. This distortion may cause a widened cast tooth when the impression material is stiff enough to resist spring-back (figure 16). Selection of the correct viscosity VPS is important to prevent tray distortion during insertion that will affect the final impression's accuracy. Use of a medium-body (monophase) VPS as the main tray material may allow the tray to distort when it contacts soft tissue or teeth, and an elongated cast tooth results as the tray springs back (figure 16). When using dual-arch trays, it is

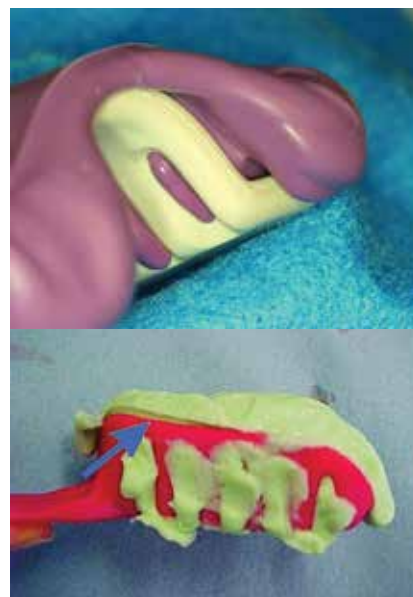

FIGURE 15: Appearance of an inaccurate impression due to separation of the impression material from the tray (arrow).



FIGURE 16: (Top) Distortion of the dual-arch can occur from contact with the tray during set of the material or inadequate stiffness of the set material. (Bottom) An impression without distortion.

recommended to use a rigid-setting VPS material (a heavy body or tray material) as the bulk of the impression to provide stability.¹⁰ Two-phase impressions can be used to create a custom format using the dual-arch tray. The preliminary impression creates a rigid base that will provide hydraulic pressure to force the wash material in and around the preparation, and a high-viscosity, stiff-setting material is used in the tray for the initial impression, and then relined with a wash material as the second step. Trimming the interproximal material from the preliminary impression will aid in seating the wash impression fully when the wash phase is performed. Wash material may not physically bond to previously set tray materials when used in a two-step impression technique, allowing the wash material to peel off the tray material. Additionally, proper selection of a tray that does not contact the teeth and is rigid enough to resist distortion is critical.

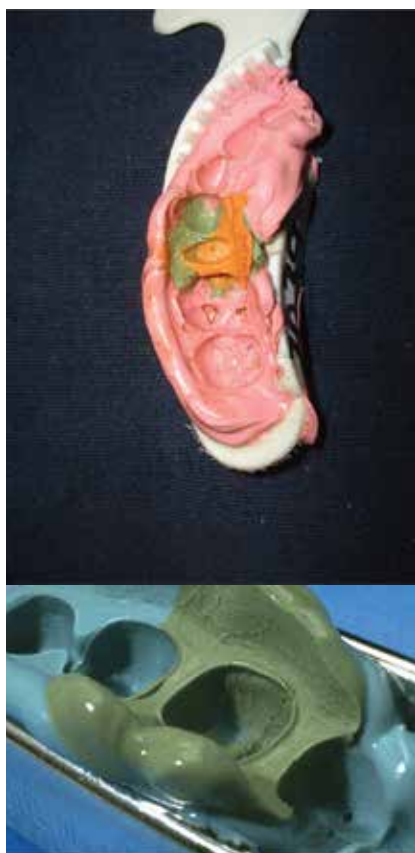


FIGURE 17: Inadequate application of wash material taken as a two-part impression leading to a “step” in the material.

Insufficient syringe material

When insufficient wash material is placed using a two-phase impression technique, a “stepped” impression may result (figure 17). These restorations will require excessive occlusal adjustment. This can be avoided by filling the entire set material in the tray in all the teeth depressions with the wash material, to provide a uniform impression.

Surface contamination

Unset impression material on the surface of the set tray material is a less common problem that may present as an unset tacky layer (figure 18). Exposure to air-inhibited methacrylates (e.g., composites, adhesives, core buildup materials, bis-acryl temporary crown and bridge materials) may leave a greasy coat on the prepared tooth that inhibits the impression material’s ability to set correctly. When using two-step impressions, failure of the wash material to adhere to the tray material may occur when the preliminary impression is utilized to fabricate the temporary prosthesis. Wiping down both the tooth and preliminary impression with alcohol to remove the greasy air-inhibited layer can prevent these issues. A better, more predictable, approach is to use a separate impression to fabricate the provisional restoration and a new impression for lab fabrication of the prosthesis.

Inhibition of the setting reaction of the marginal VPS material may result from hemostatic agents, which may transfer sulfur to critical areas of the impression. These include retraction cords and solutions containing ferric sulfate or aluminum chloride; powdered latex glove contact of the prepared teeth or surrounding tissues; or the use of a latex rubber dam. Rinsing the area with mouthwash or water after rubber dam removal and thoroughly drying can avoid this problem when impressions will be taken at the same appointment. Latex contamination of the putty can occur when mixing a VPS putty by hand, which can be avoided by washing gloved hands to remove any residual powder and surface sulfides. Powder-free latex, nitrile, or vinyl gloves are alternatives to prevent putty contamination.

When a small area of unset material is noted in the final impression, but the

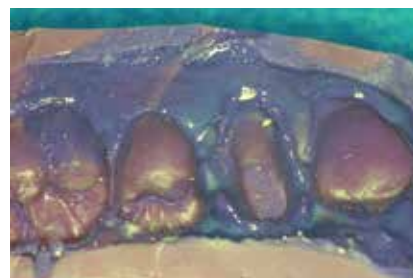

FIGURE 18: Unset VPS impression material resulting from surface contamination preventing complete polymerization of the impression material.

remainder of the material has set properly, this may be the result of a failure to bleed the cartridge prior to expressing material from the automix tip. All new cartridges should be “bled” prior to use without a mix tip on the cartridge. It should be standard practice to express a small amount of base and catalyst prior to placement of an automix tip each time to ensure that both materials are flowing from the cartridge and have not set at the end of the cartridge.

Disinfection of the completed impression can be performed either prior to sending the impression to the laboratory or at the laboratory. Immersion of the impression in common disinfecting solutions (e.g., phenols and glutaraldehydes) used for periods up to 60 minutes have not shown clinically significant distortion or surface alteration of the impression material.^{11,12} However, overnight immersion is not recommended, as this may result in a decrease in accuracy of the final cast.¹³

Inadequate impression material mixing

Once the impression material is combined, it should be uniform in color with no streaking. Streaking is more common



FIGURE 19: Streaking of the impression material resulting from inadequate mixing.

with hand-mixed putty materials than with cartridge materials (figure 19). When hand-mixing putty, the material should be kneaded quickly to stay within the working time and yield a uniform color when completed. However, streaking may also occur if the automix cartridge is not bled prior to attaching the mixing syringe, allowing one component to extrude out of the cartridge first. Standard operating procedure should be to bleed the cartridge right before a new automix tip is placed to ensure both base and catalyst are equally flowing to avoid mixing issues.

Discrepancies in the cast

A cast with large bubbles will correspond to a defect in the impression material and should be identified before dismissing the patient so that a new impression or a wash in the defective impression can be taken to correct the problem prior to sending it to the lab (figure 20). Invariably, those bubbles are caused by insufficient impression material in the tray or air trapped between the impression material and the arch during tray insertion. These defects can be avoided by syringing material around the teeth and into the vestibule prior to tray insertion. It is also advisable in patients with deep palates to place some impression material into the depth of the palatal vault to ensure capture of that area, especially when removable prosthetics are planned with that impression. As these large bubbles are more frequent in maxillary impressions, how the filled tray is inserted also plays a factor. Inserting the tray posteriorly first will not only limit

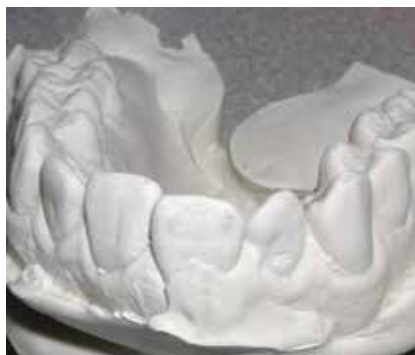

FIGURE 20: Appearance of a cast created using an impression that contained a void. Note the lack of definite detail.

impression material extruding out the back, which may cause gagging, but also pushes impression material anteriorly as the tray is rotated into position, and with it, the air that might become trapped is pushed out of the anterior of the tray.

Should a void in the impression be present upon tray removal due to air entrapment, a wash impression can be used to fill the void. It is advisable that the interproximal material be removed from the impression to allow full seating and the entire tray be covered in the wash material to ensure a continuous impression with no “step” appearance. Large bubbles in the impression when presenting in noncritical areas of the opposing arch may not require a wash in the impression to fill the void. But that is up to the practitioner to decide what the laboratory ideally needs to create the prosthetics being requested.

A cast that is covered with multiple tiny voids (bubbles) when the impression does not have corresponding defects may be the result of hydrogen gas release from the impression (figure 21). Hydrogen is a by-product of VPS polymerization. Should the cast present with this defect, if the impression is still intact, it can be repoured. This type of defect can be avoided by following the manufacturer’s recommendation with regard to the timing prior to pouring the cast. Typically, waiting 30 minutes or longer before pouring the impression is sufficient to allow it to “de-gas.” This is not a concern if the impressions will be sent to the lab to be poured.

Implant impressions

Impressions for implants involving physical impression materials are divided into two categories: open-tray and closed-tray



FIGURE 21: The cast is covered with multiple bubbles resulting from hydrogen gas release from the VPS material due to pouring of cast too early.

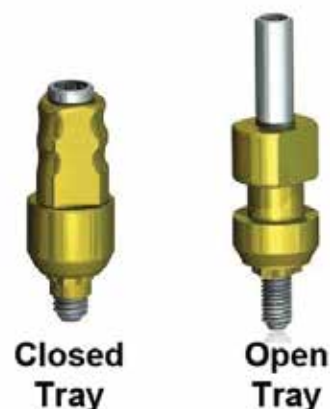


FIGURE 22: Geometric differences between a closed and open implant coping.

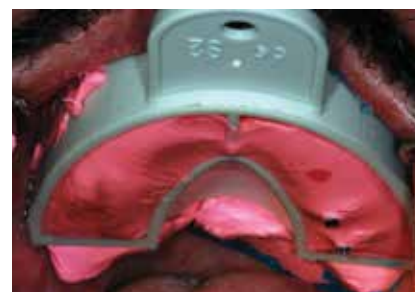

FIGURE 23: An open-tray impression intraorally demonstrating the long pins piercing the impression.

impressions. The impression copings for open- and closed-tray techniques differ in geometry (figure 22).^{14,15} An open-tray impression requires that the impression coping is retained in the impression, and they are removed together intraorally. These have a long pin that protrudes through the impression and tray, which is removed prior to removal of the impression intraorally (figure 23). Whereas when a closed-tray impression is taken, the impression is removed intraorally, leaving the impression coping attached to the implant. The impression coping is then removed intraorally, an analog is attached to the closed-tray coping, and it is reinserted back into the impression extraorally (figure 24). The impression material selected is dependent on which type of impression will be taken. A stiffer tray material (a heavy body or tray VPS) is required when taking an open-tray impression to lock the impression copings into position so that they are oriented to each other and the connector

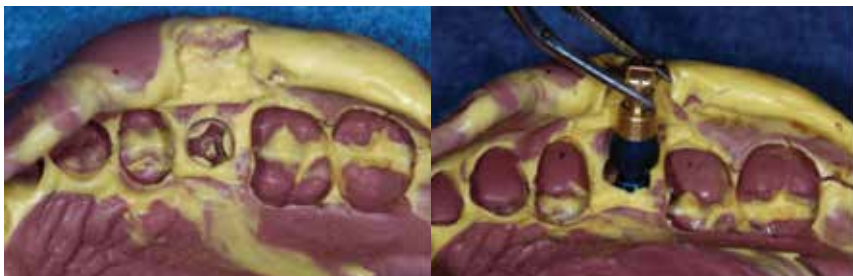


FIGURE 24: (Left) Closed-tray implant impression following removal intraorally and (right) reinserting the closed-tray impression coping with analog attached back into the impression.

rotation is captured, so the resulting master soft tissue model is accurate. Closed-tray impressions need a more resilient viscosity of impression material, as the coping must be resealed into the impression extraorally. A medium-body (monophase) VPS is ideally suited for this application, allowing the impression to spring off the coping as it is removed intraorally and allow it to be reinserted into the impression to fabricate the master soft-tissue model. If a stiff VPS such as a heavy body were used, it might tear around the copings when it is removed intraorally and would hamper full seating of the coping back into the impression. It is advised with both an open-tray or closed-tray approach that a wash material be syringed around the gingival aspect only, to capture the gingival position better than may be achieved with the material in the tray alone, and to avoid any potential bubbles in that area of the set impression.

Conclusion

Complications during the impression process can be perplexing to both the dentist and laboratory technician. Some common impression issues include tearing, voids, bubbles, and tray contact. Identifying the problem is only half the solution. Understanding why it occurred helps guide the practitioner to correct the issue and prevent future occurrences. This article addressed solutions for correction of some of the most prevalent impression issues that are experienced in clinical practice. By taking the necessary precautions, clinicians can ensure improved accuracy in communication of critical parameters as well as an overall improvement in restorative fit related to

their impressions.

References

1. Shannon A. Expanded clinical uses of a novel tissue-retraction material. *Compend Contin Educ Dent*. 2002;23(1 Suppl):3-6.
2. Poss S. An innovative tissue-retraction material. *Compend Contin Educ Dent*. 2002;23(1 Suppl):13-17.
3. Pescatore C. A predictable gingival retraction system. *Compend Contin Educ Dent*. 2002;23(1 Suppl):7-12.
4. Kurtzman GM, Agarwal T. Laser troughing to improve scanning and impressions. *Dent Today*. 2017;36(1):122-125.
5. Hondrum SO. Tear and energy properties of three impression materials. *Int J Prosthodont*. 1994;7(6):517-521.
6. Chai J, Takahashi Y, Lautenschlager EP. Clinically relevant mechanical properties of elastomeric impression materials. *Int J Prosthodont*. 1998;11(3):219-223.
7. Brosky ME, Pesun IJ, Lowder PD, et al. Laser digitization of casts to determine the effect of tray selection and cast formation technique on accuracy. *J Prosthet Dent*. 2002;87(2):204-209.
8. Thongthammachat S, Moore BK, Barco MT 2nd, et al. Dimensional accuracy of dental casts: influence of tray material, impression material, and time. *J Prosthodont*. 2002;11(2):98-108.
9. Giordano R 2nd. Issues in handling impression materials. *Gen Dent*. 2000;48(6):646-648.
10. Ceyhan JA, Johnson GH, Lepe X. The effect of tray selection, viscosity of impression material, and sequence of pour on the accuracy of dies made from dual-arch impressions. *J Prosthet Dent*. 2003;90(2):143-149.
11. Rios MP, Morgano SM, Stein RS, Rose L. Effects of chemical disinfectant solutions on the stability and accuracy of the dental impression complex. *J Prosthet Dent*. 1996;76(4):356-362.
12. Oda Y, Matsumoto T, Sumii T. Evaluation of dimensional stability of elastomeric impression materials during disinfection. *Bull Tokyo Dent Coll*. 1995;36(1):1-7.
13. Lepe X, Johnson GH. Accuracy of polyether and addition silicone after long-term immersion disinfection. *J Prosthet Dent*. 1997;78(3):245-249.
14. Agarwal S, Ashok V, Maiti S. Open- or closed-tray impression technique in implant prosthesis: a dentist's perspective. *J Long Term Eff Med Implants*. 2020;30(3):193-198. doi:10.1615/JLongTermEffMedImplants.2020035933
15. Moreira AH, Rodrigues NF, Pinho AC, et al. Accuracy comparison of implant impression techniques: a systematic review. *Clin Implant Dent Relat Res*. 2015;17(Suppl 2):e751-64. doi:10.1111/cid.12310



GREGORI M. KURTZMAN, DDS, MAGD, DADIA, DICOI, DIDIA, FACD, FPFA, is in private general dental practice in Silver Spring, Maryland, and is a former assistant clinical professor at the University of Maryland in the department of restorative dentistry and endodontics. He is a former AAID Implant Maxi-Course assistant program director at Howard University College of Dentistry. Dr. Kurtzman has lectured internationally on the topics of restorative dentistry; endodontics, implant surgery, and prosthetics; removable and fixed prosthetics; and periodontics. He has published more than 760 articles and several e-books and textbook chapters. He has earned fellowship in the Academy of General Dentistry (AGD), American College of Dentists (ACD), International Congress of Oral Implantologists (ICOI), Pierre Fauchard Academy, and Academy of Dentistry International (ADI); mastership in the AGD and ICOI; and diplomate status in the ICOI, Association of Dental Implant Auxiliaries (ADIA), and the International Dental Implant Association (IDIA). Dr. Kurtzman is a consultant and evaluator for multiple dental companies and has been honored to be included in the "Top Leaders in Continuing Education" annually since 2006. He can be reached at dr_kurtzman@maryland-implants.com.

Use this page to review questions and answers. Visit dentalacademyofce.com and sign in. If you have not previously purchased the course, select it from the Online Courses listing and complete your online purchase. Once purchased, the exam will be added to your Archives page, where a Take Exam link will be provided. Click on the Take Exam link, complete all the program questions, and submit your answers. An immediate grade report will be provided. Upon receiving a grade of 70% or higher, your verification form will be provided immediately for viewing and printing. Verification forms can be viewed and printed at any time in the future by visiting the site and returning to your Archives page.

QUESTIONS

1. Which is not a common complaint from labs regarding the impressions they receive?
 - A. Voids on the marginal material
 - B. Torn sulcular material
 - C. Inadequate marginal detail
 - D. Impression materials extending apical to the preparation's margins
2. Failure to capture the preparation's marginal details will result in:
 - A. Short restoration margins
 - B. Overextended restorative margins
 - C. Open restorative margins
 - D. A and C
3. Which method is used to better visualize the restorative margin to capture with an impression?
 - A. Retraction cords and pastes
 - B. Hemostatic VPS
 - C. Diode or Er:YAG laser
 - D. All of the above
4. When internal bubbles are noted in the preparation in the impression, these may be due to:
 - A. Poor tooth preparation
 - B. Unset impression material
 - C. Trapped moisture
 - D. Trapped food
5. Which problem in the impression can affect the fit of the subsequent restoration?
 - A. Bubbles on the opposing arch
 - B. Bubbles at the margins
 - C. Bubbles at internal line angles
 - D. Bubbles on teeth not being restored that are not adjacent to the prep
6. When a bubble on the internal line angle of the prep is noted on the cast, it is recommended to:
 - A. Scrape off the bubble on the cast
 - B. Ignore the bubble, as it won't affect fabrication of the restoration
 - C. Block out the area on the cast around any size bubble
 - D. Block out the area on the cast around the bubble if it is small
7. When large bubbles are noted in the impression at internal line angles, they:
 - A. Will not affect the integrity of the restoration fabricated
 - B. May be altered on the cast to remove before restoration fabrication
 - C. Compromise the strength of metal-based restorations fabricated on the cast
 - D. Compromise the strength of ceramic restorations fabricated on the cast
8. When utilizing a two-step impression technique:
 - A. Place wash material over all tooth areas in the set tray material before reinserting intraorally
 - B. Avoid drying the set material in the tray
 - C. Trim the interproximal impression material with scissors in the set tray material before step two
 - D. A and C
9. When taking an impression to capture an occlusal or interproximal preparation, it is advised to:
 - A. Utilize a two-step technique
 - B. Place an intraoral tip to the bottom of the preparation and backfill it to prevent air entrapment
 - C. Avoid use of a heavy body VPS
 - D. Use a wash material placed into the tray over the unset tray material
10. When an inlay/onlay restoration is not seating on the preparation, identification of internal premature contacts can be aided by:
 - A. Use of articulating film instead of articulating paper
 - B. Liquid occlusal indicator
 - C. Relief of the entire preparation with a bur/diamond
 - D. Relief of the entire internal area of the restoration with a bur/diamond
11. When marginal tears occur in the impression material, these are related to:
 - A. Premature removal of the impression intraorally before setting has completed
 - B. Deep margins with a narrow sulcus
 - C. Low wash material tear strength
 - D. All of the above
12. Regarding marginal tearing potential, which viscosity impression material will be stronger in a deeper sulcus to capture needed detail?
 - A. Very light body VPS
 - B. Light body VPS
 - C. Medium body VPS
 - D. Universal body VPS
13. A heavier body VPS in the tray may result in:
 - A. Lack of adhesion to the wash material when doing a one-step technique
 - B. Drags due to air entrapment
 - C. Drags related to the cusps when inserted
 - D. Longer setting time
14. When the working time of the impression material is exceeded, this can result in:
 - A. Difficult removal of the impression intraorally
 - B. Drags and folds
 - C. Failure of the wash material and tray material to adhere to each other
 - D. No effect on the final impression
15. The best method to avoid drags and pulls when using heavy body material in the tray is:
 - A. A two-step technique
 - B. A one-step technique
 - C. To syringe wash material around all of the teeth before inserting the previously set tray material
 - D. To syringe wash material around all of the teeth before inserting the unset tray material

Use this page to review questions and answers. Visit dentalacademyofce.com and sign in. If you have not previously purchased the course, select it from the Online Courses listing and complete your online purchase. Once purchased, the exam will be added to your Archives page, where a Take Exam link will be provided. Click on the Take Exam link, complete all the program questions, and submit your answers. An immediate grade report will be provided. Upon receiving a grade of 70% or higher, your verification form will be provided immediately for viewing and printing. Verification forms can be viewed and printed at any time in the future by visiting the site and returning to your Archives page.

QUESTIONS


- 16. To achieve the most accurate results when using a dual-arch tray:**
- Use a medium body VPS in the tray
 - Use a heavy body or tray VPS in the dual-arch tray
 - Viscosity of the tray material is not important
 - Use the same methods used with single-arch trays
- 17. When selecting a tray:**
- Select a wide enough tray to prevent show-through of the tray in the completed impression
 - Recognize that patient arches vary and one manufacturer's trays may not fit all arches
 - Make sure the tray does not contact soft tissue when inserted
 - All of the above
- 18. When a full-arch impression is to be taken:**
- Tray contact with soft tissue is not important
 - Select a tray that is long enough to capture the teeth being treated
 - Select a tray that is long enough to capture the entire arch
 - Select a tray that contacts the soft tissue posteriorly for stability when taking the impression
- 19. When using a dual-arch tray in the posterior, it is important that:**
- There is contact with the posterior loop to help stabilize the occlusion of the impression
 - Contact with the tray be evident to ensure an accurate impression
 - Show-through on the occlusal surface is not visible
 - Upon biting, there is no contact with the posterior loop
- 20. To avoid separation of the impression material from the tray:**
- Add holes or slots to the stock tray to improve retention
 - Use a tray with adequate retentive elements
 - Coat the tray in a compatible adhesive
 - All of the above
- 21. An impression that has a "stepped" appearance may result from:**
- Different brands of VPS being used together
 - Working time of the materials being exceeded
 - Inadequate wash material in a two-step technique
 - Inadequate wash material in a one-step technique
- 22. When the VPS impression surface has unset material on it, this may be a result of:**
- Contact with blood
 - Contact with nitrile gloves
 - Contact with powder-free latex gloves
 - Contact with oxygen-inhibited methacrylates
- 23. It is important to bleed the automix cartridge to ensure:**
- Complete mixing through the automix tip
 - The material has not expired
 - Flow of base and catalyst from the cartridge
 - A and C
- 24. When disinfecting an impression, you may:**
- Spray with disinfectant and immediately rinse off
 - Wrap the impression in a disinfectant wipe and seal in a zip-lock bag before sending to the lab
 - Immerse in approved disinfecting solution overnight
 - Immerse in approved disinfecting solution for up to 60 minutes
- 25. When taking a VPS impression, one should:**
- Pour the impression immediately
 - Wait at least 30 minutes before pouring
 - Wait overnight before pouring
 - Pour the impression before sending to the lab for maximum accuracy of the cast
- 26. When the cast is covered with multiple tiny bubbles that are not in the impression, it is an indication that:**
- The impression was dry before it was poured
 - Moisture was present on the impression before it was poured
 - The impression did not have adequate time to de-gas
 - The impression material was not compatible with the stone used to fabricate the cast
- 27. When taking an implant open-tray impression:**
- VPS should not be used as the impression material
 - A medium body VPS is recommended
 - A heavy body VPS is recommended
 - Any viscosity VPS may be used
- 28. When taking an implant closed-tray impression:**
- VPS should not be used as the impression material
 - A medium body VPS is recommended
 - A heavy body VPS is recommended
 - Any viscosity VPS may be used
- 29. When a heavy body or tray VPS material is used to capture an implant closed tray impression, which problem may occur?**
- Reinsertion of the coping back into the impression extraorally may not be accurate
 - No problems will result using a tray material
 - Impression may tear upon removal of the impression intraorally
 - A and C
- 30. When taking an implant impression, it is recommended to use an open-tray technique because it:**
- Is more accurate than taking a closed-tray impression
 - Locks the impression copings accurately in relation to other adjacent implants
 - Accurately captures the implant's rotational orientation
 - All of the above

Dental impression problems: Identifying and managing

NAME:	TITLE:	SPECIALTY:	
ADDRESS:	EMAIL:	AGD MEMBER ID (IF APPLIES):	
CITY:	STATE:	ZIP:	COUNTRY:
TELEPHONE (PRIMARY):	TELEPHONE (OFFICE):		

REQUIREMENTS FOR OBTAINING CE CREDITS BY MAIL/FAX: 1) Read entire course. 2) Complete info above. 3) Complete test by marking one answer per question. 4) Complete course evaluation. 5) Complete credit card info or write check payable to Endeavor Business Media. 6) Mail/fax this page to DACE. If you have any questions, please contact dace@endeavor2b.com or call (800) 633-1681. A score of 70% or higher is required for CE credit.

COURSE CAN ALSO BE COMPLETED ONLINE AT A LOWER COST. Scan the QR code or go to dentalacademyofce.com to take advantage of the lower rate.



Educational Objectives

- Identify common impression problems
- Correct common impression problems
- Improve impression quality and avoid impression problems
- Select impression materials that are best suited for specific restorative objectives

Course Evaluation

- Were the individual course objectives met?

Objective #1: Yes No Objective #3: Yes No
 Objective #2: Yes No Objective #4: Yes No

Please evaluate this course by responding to the following statements, using a scale of Excellent = 5 to Poor = 0.

- To what extent were the course objectives accomplished overall? 5 4 3 2 1 0
- Please rate your personal mastery of the course objectives. 5 4 3 2 1 0
- How would you rate the objectives and educational methods? 5 4 3 2 1 0
- How do you rate the author's grasp of the topic? 5 4 3 2 1 0
- Please rate the author's effectiveness. 5 4 3 2 1 0
- Was the overall administration of the course effective? 5 4 3 2 1 0
- Please rate the usefulness and clinical applicability of this course. 5 4 3 2 1 0
- Please rate the usefulness of the references. 5 4 3 2 1 0
- Do you feel that the references were adequate? Yes No
- Would you take a similar course on a different topic? Yes No
- If any of the continuing education questions were unclear or ambiguous, please list them.

13. Was there any subject matter you found confusing? Please describe.

14. How long did it take you to complete this course?

15. What additional dental continuing education topics would you like to see?

Mail/fax completed answer sheet to:

Endeavor Business Media

Attn: Dental Division
 7666 E. 61st St. Suite 230, Tulsa, OK 74133
 Fax: (918) 831-9804

Payment of \$69 is enclosed (this course can be completed online for \$59. Scan the QR code or go to dentalacademyofce.com to take advantage of the lower rate).

Make check payable to Endeavor Business Media

If paying by credit card, please complete the following:

MC Visa AmEx Discover

Acct. number: _____

Exp. date: _____ CVC #: _____

Billing address: _____

Charges on your statement will show up as Endeavor.

- | | |
|---------------------|---------------------|
| 1. (A) (B) (C) (D) | 16. (A) (B) (C) (D) |
| 2. (A) (B) (C) (D) | 17. (A) (B) (C) (D) |
| 3. (A) (B) (C) (D) | 18. (A) (B) (C) (D) |
| 4. (A) (B) (C) (D) | 19. (A) (B) (C) (D) |
| 5. (A) (B) (C) (D) | 20. (A) (B) (C) (D) |
| 6. (A) (B) (C) (D) | 21. (A) (B) (C) (D) |
| 7. (A) (B) (C) (D) | 22. (A) (B) (C) (D) |
| 8. (A) (B) (C) (D) | 23. (A) (B) (C) (D) |
| 9. (A) (B) (C) (D) | 24. (A) (B) (C) (D) |
| 10. (A) (B) (C) (D) | 25. (A) (B) (C) (D) |
| 11. (A) (B) (C) (D) | 26. (A) (B) (C) (D) |
| 12. (A) (B) (C) (D) | 27. (A) (B) (C) (D) |
| 13. (A) (B) (C) (D) | 28. (A) (B) (C) (D) |
| 14. (A) (B) (C) (D) | 29. (A) (B) (C) (D) |
| 15. (A) (B) (C) (D) | 30. (A) (B) (C) (D) |

EXAM INSTRUCTIONS

We encourage participant feedback. Complete the evaluation above and e-mail additional feedback to Aileen.Southerland@endeavor2b.com and Laura.Winfield@endeavor2b.com. Participants will receive confirmation of passing by receipt of a Verification of Participation form. The form will be mailed within two weeks after receipt of an examination.

COURSE EVALUATION AND FEEDBACK

We encourage participant feedback. Complete the evaluation above and e-mail additional feedback to Aileen.Southerland@endeavor2b.com and Laura.Winfield@endeavor2b.com.

COURSE CREDITS AND COST

All participants scoring 70% or higher on the examination will receive a verification form for three (3) continuing education (CE) credits. Participants are urged to contact their state dental boards for CE requirements. The cost for courses ranges from \$20 to \$110.

PROVIDER INFORMATION

Endeavor Business Media is an ADA CERP-recognized provider. ADA CERP is a service of the American Dental Association to assist dental professionals in identifying quality providers of continuing dental education. ADA CERP neither approves nor endorses individual courses or instructors, nor does it imply acceptance of credit hours by boards of dentistry. Concerns about a CE provider may be directed to the provider or to ADA CERP at ada.org/cefp.

Endeavor Business Media is designated as an approved PACE program provider by the Academy of General Dentistry. The formal continuing dental education programs of this program provider are accepted by the AGD for fellowship, mastership, and membership maintenance credit. Approval does not imply acceptance by a state or provincial board of dentistry or AGD endorsement. The current term of approval extends from 1/1/2019 to 3/31/2022. Provider ID# 020452. AGD Code: Impression demonstration steps appearance and registration approval.

Dental Board of California: Provider RP5933. Course registration number CA code: 03-5933-21089. Expires 7/31/2022. *This course meets the Dental Board of California's requirements for three (3) units of continuing education.*

Endeavor Business Media is designated as an approved provider by the American Academy of Dental Hygiene Inc. #AADHPNW (January 1 2021 - December 31, 2022). Approval does not imply acceptance by a state or provincial board of dentistry. Licensee should maintain this document in the event of an audit.

RECORD KEEPING

Endeavor Business Media maintains records of your successful completion of any exam for a minimum of six years. Please contact our offices for a copy of your CE credits report. This report, which will list all credits earned to date, will be generated and mailed to you within five business days of receipt.

CANCELLATION AND REFUND POLICY

Participants who are not 100% satisfied can request a refund by contacting Endeavor Business Media in writing.

IMAGE AUTHENTICITY

The images in this educational activity have not been altered.

© 2021 Academy of Dental Therapeutics and Stomatology, a division of Endeavor Business Media